

PATIENT PRESENTING CLINICAL SIGNS

Koffee Aska History: Acute onset seizures, ataxia, intention type tremors. Responded to lactulose, metronidazole, fenbendazole, and clavamox.

SPECIES Physical Examination: N/A.

Canine Urinalysis: N/A.

BREED CBC: N/A.

Minature Poodle Serum Biochemistry: Elevated liver enzyme activity and bile acids. Mild hypoglycemia. CRP, clotting profile, Accuplex, and distemper PCR pending

SEX Radiographic Findings: N/A.

Female

AGE ULTRASONOGRAPHIC EXAMINATION OF THE ABDOMEN

1 year **Urinary System**

WEIGHT Full urinary bladder with a normal thickness and appearance of the wall. Normal anechoic urine with no sediment or uroliths evident.

4.3 # Normal trigone area, proximal urethra, and iliac blood vessels.

INTERPRETED BY Normal iliac lymph nodes. Ureters not visualized.

Remo Lobetti, BVSc, MMedVet (Med), PhD, Dipl. ECVIM Normal renal size (left 3.6 cm, right 3.4 cm), echogenic appearance, cortico-medullary differentiation, pelvis, and capsule.

Reproductive System

IMAGING PERFORMED BY N/A.

Adrenal Glands

Normal shape, echogenic appearance, position, and size. Left 1.05 x 0.39 cm, right 0.62 x 0.33 cm.

HOSPITAL NAME **Spleen**

Central Broward Animal Hospital

REFERRING VET Normal size and echogenic appearance. Smooth homogenous parenchyma, regular curvilinear capsule, and normal vasculature. No evidence of inflammatory, neoplastic, infarction, or infiltrative changes noted.

Dr Megan Cassels-Conway, DVM

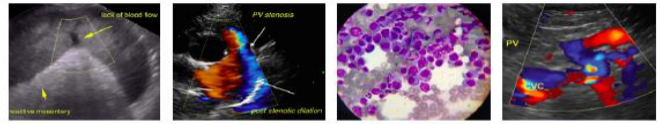
Liver

INVOICE Normal size, echogenic appearance, portal markings, and curvilinear capsule. No nodules or masses evident. Full gall bladder containing normal anechoic bile. Normal appearance and thickness of the gall bladder wall. Normal bile duct.

303859

DATE

2/5/23



PATIENT *Gastrointestinal*

Koffee Aska
Normal appearance of the stomach, duodenum, small intestine, ileo-cecal junction, and colon with no loss of layering, normal wall thickness and peristaltic activity, and no distension of the lumen. Ingesta within the stomach, chyle within the small intestine.

SPECIES

Canine *Pancreas*

Normal size and echogenic appearance. Normal echogenic appearance of the mesentery and fat surrounding the pancreas.

BREED

Minature Poodle *Free Abdomen*

SEX
No mesenteric lymphadenomegaly.
No ascites.

Female
Normal size and ratio of the portal vein, caudal vena cava, and aorta.

AGE
No obvious turbulent blood flow evident.

1 year

ULTRASONOGRAPHIC FINDINGS

WEIGHT

4.3 #

Primary Findings:

- None.

Secondary Findings:

- None.

INTERPRETED BY

Remo Lobetti, BVSc,
MMedVet (Med), PhD, Dipl.
ECVIM

INTERPRETATION OF THE FINDINGS & FURTHER RECOMMENDATIONS

Normal ultrasound examination of the abdomen.

If hepatic encephalopathy is still likely, then CT angiogram and liver biopsy should be considered.

IMAGING PERFORMED BY

Dr Megan Cassels-Conway,
DVM

HOSPITAL NAME

Central Broward Animal
Hospital

REFERRING VET

Dr Megan Cassels-Conway,
DVM

The information and recommendations provided are based on the images presented by the referring veterinarian. No evaluation can be communicated regarding pathology that was not visible in the image/video clips provided.

Thank you for this referral. If the clinical or image interpretation does not parallel your findings or if I can be of any further assistance, please contact me.

INVOICE

303859

Remo Lobetti, BVSc, MMedVet (Med), PhD, Dipl. ECVIM (Internal Medicine)
rlobetti@mweb.co.za

DATE

2/5/23